

Radiologic Evaluation of Uterine Scar Defect on Cesarean Section Scar Before and After Metroplastic Corrective Surgery: Case Report

Sezaryen Skarındaki Defektin Metroplastik Düzeltici Cerrahi Öncesi ve Sonrası Radyolojik Değerlendirilmesi

İsmail CEPNİ, MD,^a
Tayfur ÇİFT, MD,^a
Pelin ÖCAL, MD,^a
Eray BALCAN, MD,^a
Berk BULUT, MD,^a
Suat KARATAŞ, MD^a

^aDepartment of Gynecology and Obstetrics, İstanbul University Cerrahpaşa Faculty of Medicine, İstanbul

Geliş Tarihi/Received: 17.10.2009
Kabul Tarihi/Accepted: 18.01.2010

Yazışma Adresi/Correspondence:
Tayfur ÇİFT, MD
İstanbul University
Cerrahpaşa Faculty of Medicine,
Department of Gynecology and
Obstetrics, İstanbul,
TÜRKİYE/TURKEY
tayfur_cift@yahoo.com

ABSTRACT Tissue defects which seen on uterine scars of the cesarean sections are encountered rarely. The defects that are not causing a specific symptom can be identified by a detailed ultrasonography (USG) or hysterosalpingography (HSG). In this case report, a defect which is originated from the scar tissue of cesarean section will be presented. The patient had one child and she was being investigated because of secondary infertility. A defect was visualized on the uterine scar tissue due to prior cesarean section in USG and it was confirmed with HSG. Uterin defect was corrected by a metroplasty operation and after one month, transvaginal USG revealed a completely intact uterin scar site. Patients who underwent uterine operations such as cesarean section should be evaluated by USG and it must be made sure that the uterine scar healed completely.

Key Words: Cesarean section; uterine rupture; gynecologic surgical procedures

ÖZET Sezaryen sonrası uterin skar dokusunda gelişmiş defekt çok sık rastlanan bir durum değildir. Spesifik bulgu vermeyen defekt genelde detaylı yapılan ultrasonografi (USG) ya da histerosalpingografi (HSG) sonrası belirlenebilir. Bu olgu sunumunda sezaryen sonrası uterin skar dokusunda gelişmiş defekt sunulacaktır. Daha önce bir doğumu olan hastanın, sekonder infertilite nedeniyle araştırılması esnasında USG’de uterin skar dokusunda defekt gözlenmiş ve HSG ile doğrulanmıştır. Uterin defekt hastaya laparotomi uygulanarak metroplastik ameliyatı ile düzeltilmiştir ve postoperatif bir ay sonra yapılan transvajinal USG’de uterin skardaki defektin kapandığı gözlenmiştir. Sezaryen gibi uterus ameliyatı geçirmiş hastalar USG ile değerlendirilmeli, uterusunda bulunan insizyonun tam olarak iyileştiğinden emin olunmalıdır.

Anahtar Kelimeler: Sezaryen; uterus rüptürü; jinekolojik cerrahi işlemler

Türkiye Klinikleri J Gynecol Obst 2010;20(3):207-10

Nowadays, routine examination in Obstetrics and Gynecology practice commonly involves the usage of transvaginal, transrectal or transabdominal USG. Apart from pathologic conditions, it is an objective evaluation method for the detection of scars on the uterus. Cesarean section (C/S) can be performed safely today and is becoming more widespread everyday. However, a number of complications which were seen rarely before, those that uterine rupture in the pregnancy after a prior cesarean section, placenta previa/accreata, pregnancy on scar tissue of the prior cesarean section are increasing. Moreover, patients meet with difficulties such as uterine defects developing on cesarean scar tissues. In our case the patient was discharged from the hospital after C/S has been per-

formed but the patient failed to attend regular control visits. Afterwards the patient admitted to our clinic with a complaint of secondary infertility and a defect on the uterine scar tissue was detected during the routine USG examination. Informed consent was obtained from the patient for this study.

CASE REPORT

A 29 year-old woman, gravida 1, para 1 (G1P1A0C0), applied with the complaint of secondary infertility. The patient had no systemic problems before and she had two operations, which were a cesarean section in 2000 bring forth with a live birth, and a left oophorectomy because of an ovarian cyst in 2004. The pathology result of the oophorectomy was an endometrioma. The patient who was being investigated because of secondary infertility meanwhile she was also complained about non-specific symptoms during menstrual periods in the lower abdominal region. On the hysterosalpingography, opaque material was visualized outside the uterine cavity (Figure 1). In transvaginal USG, an area of detachment was diagnosed and the patient was directed to our center. A defect which was approximately 1 cm-long on uterine scar tissue could be visualized in transvaginal USG (Figure 2). The patient was hospitalized for a metroplasty operation. At the beginning of

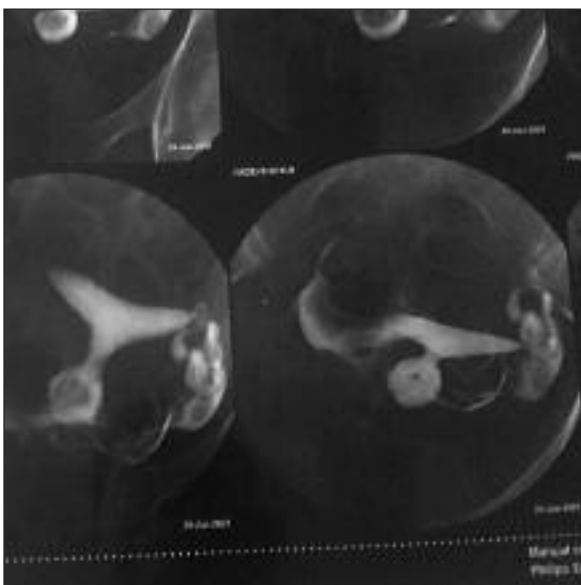


FIGURE 1: Hysterosalpingography view before operation.

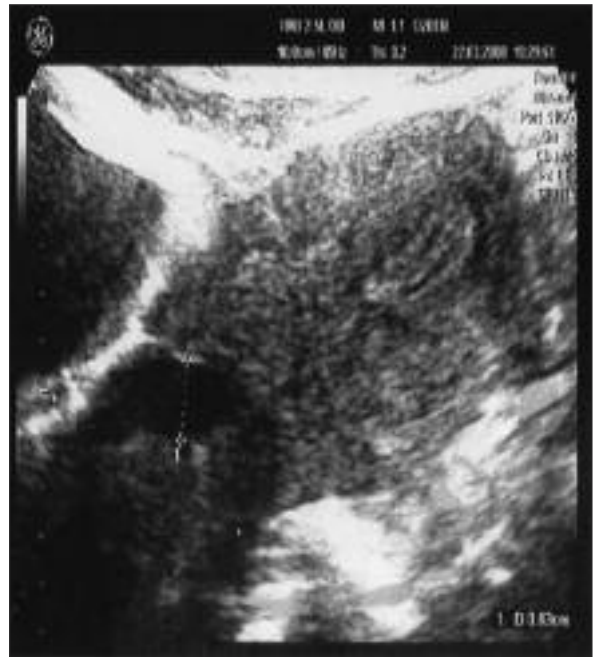

FIGURE 2: Sonographic view of the lesion.

the operation, a Pfannenstiel-type skin incision was preferred. During the exploration, an area that was approximately 1 cm in length was seen on the place which was consistent (compatible) with a prior cesarean section scar that befit at the junction of isthmic segment and uterine corpus, and the underlying cavity was covered solely by serosal layer (Figure 3). After the urinary bladder blunt dissection, the scar tissue was excised. Myometrium was sutured initially and be wary of not to involve endometrium, and serosa was closed afterwards. After the bleeding sites were cauterized operation was ended and the abdominal layers were closed in anatomical order. The patient was discharged from the hospital on post-operative second day. One month later the patient was evaluated with transvaginal USG and it was seen that the defect was completely closed (Figure 4).

DISCUSSION

In past decades the Cesarean section rate has increased markedly.¹ Cesarean section is associated with complications in subsequent pregnancies, such as scar pregnancy with life-threatening bleeding, placenta previa, placenta accreta, increta or percreta, dehiscence or uterine rupture.

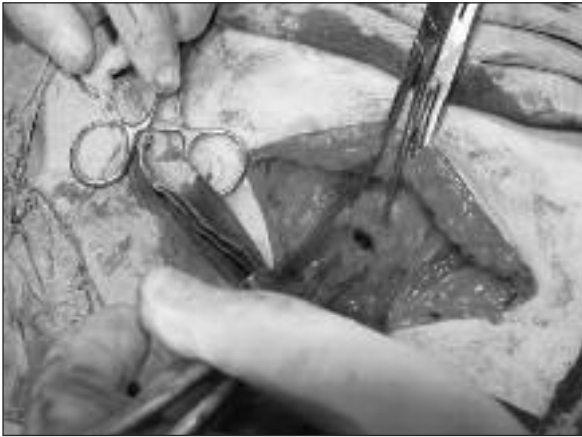

FIGURE 3: Intraoperative view of the defect.

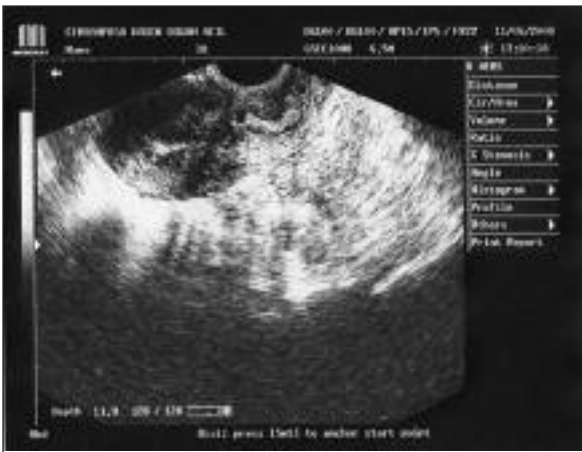

FIGURE 4: Sonographic view after surgery.

Although many incision types have been described, because of favorable surgical results, Pfannenstiel incision is preferred for cutaneous incision and Munroe-Kerr is used for uterine incision.² During surgery, uterus is closed with interlocking continuous sutures as a single layer. It is essential to pay attention to approximate myometrial edges suitably. In pregnancies after cesarean section, complications such as uterine rupture, placenta previa/accreata, and pregnancy on prior cesarean section scar are encountered more frequently.³⁻⁵ The defects on uterine scar tissues were an uncommon complications of the C/S. In this case, a defect was developed from the uterine scar tissue, and a diagnosis could only be made during infertility evaluation. The patient did not attend regular control visits also she had no complaint so the de-

fect remained undetected. The healing process in cesarean section scars is modified by many factors. In a study by Hayakawa et al in 2006, uterine closure techniques were compared and the scar tissue was re-evaluated 1 month later.⁶ Authors compared 3 conditions; single layer closure, two-layer closure and single layer decidual closure. As a result, myometrial healing was found to be associated with the uterine closure technique, and other external factors such as conditions effective on wound healing process. Another study in 2007 was performed by Hamar et al. In which post-section uterine scars were evaluated.⁷ the fixed evaluation schedule for the study was; before section, 48 hours after the operation, after 2 weeks and after 6 weeks and the thickness of the scar tissue was assessed for single layer closure and for two-layer closure. At the end of the study, USG method was considered sufficient enough to evaluate the re-formed scar tissue. Although closure techniques were not different from one another, uterine scar tissue was getting thinner during the healing process. Ofili-Yebovi et al stated that evaluating the defects occurring on the cesarean scars of the patients seemed as an helpful tool to prevent uterine ruptures during the following pregnancies and was a practical method.⁸ In the same study, the authors have also shown that USG examinations performed around 6 and 7 weeks in patients who had multiple prior cesarean sections are helpful to detect pregnancies on uterine cesarean scar in an early period of pregnancy. All Cesarean sections had been carried out using a transverse lower segment incision. So we can say that the women who had undergone Cesarean section were examined on average 6 weeks after the latest Cesarean section

The prevalence of large defects as judged subjectively by the ultrasound examiner increased with the number of Cesarean sections. However, using objective measurement criteria to define a large defect we were unable to confirm such a trend. It is possible that subjective evaluation is superior to measurements for classification of defects as large or small, because measurements are unlikely to be precise, and a difference as small as 0.1 mm would classify a defect differently.

Eventually, the patients who had prior cesarean sections should be evaluated by USG and whether there is a scar and its features should be clarified in order to prevent any complications to appear. It is not known whether defects in cesarean section scars that are visible at transvaginal

ultrasound examination of non-pregnant women are associated with a higher risk of these complications than apparently intact scars or whether large defects are associated with a higher risk of complications than small defects, but this might be the case.

REFERENCES

1. Lydon-Rochelle M, Holt VL, Easterling TR, Martin DP. Risk of uterine rupture during labor among women with a prior cesarean delivery. *N Engl J Med* 2001;(345):3-8.
2. Hofmeyr GJ, Mathai M, Shah A, Novikova N. Techniques for caesarean section. *Cochrane Database Syst Rev* 2008;(1): CD004662.
3. Clark SL, Koonings PP, Phelan JP. Placenta previa-accreta and prior cesarean section. *Obstet Gynecol* 1985;(66):89-92.
4. Çetinkaya ES, Söylemez F. [Complications of cesarean section]. *Türkiye Klinikleri J Gynecol Obst-Special Topics* 2008;1(1): 27-32.
5. Jurkovic D, Hillaby K, Woelfer B, Lawrence A, Salim R, Elson CJ. First-trimester diagnosis and management of pregnancies implanted into the lower uterine segment Cesarean section scar. *Ultrasound Obstet Gynecol* 2003; (21):220-7.
6. Hayakawa H, Itakura A, Mitsui T, Okada M, Suzuki M, Tamakoshi K, et al. Methods for myometrium closure and other factors impacting effects on cesarean section scars of the uterine segment detected by the ultrasonography. *Acta Obstet Gynecol Scand* 2006;85(4):429-34.
7. Hamar BD, Saber SB, Cackovic M, Magloire LK, Pettker CM, Abdel-Razeq SS, et al. Ultrasound evaluation of the uterine scar after cesarean delivery: a randomized controlled trial of one- and two-layer closure. *Obstet Gynecol* 2007;110(4):808-13.
8. Ofili-Yebovi D, Ben-Nagi J, Sawyer E, Yazbek J, Lee C, Gonzalez J, et al. Deficient lower segment cesarean section scars: prevalence and risk factors. *Ultrasound Obstet Gynecol* 2008;31(1):72-7.