

# Spontaneous Uterine Rupture with Retroperitoneal Hematoma in the First Trimester: Case Report

## İlk Trimesterde Retroperitoneal Hematomun Eşlik Ettiği Uterus Rüptürü

Murat AKBAŞ,<sup>a</sup>  
İbrahim ÖMEROĞLU,<sup>a</sup>  
Özer BİRGE<sup>a</sup>

<sup>a</sup>Clinic of Gynecology and Obstetrics,  
Ağrı Maternity Hospital, Ağrı

Geliş Tarihi/Received: 05.02.2014  
Kabul Tarihi/Accepted: 25.04.2014

Yazışma Adresi/Correspondence:  
Murat AKBAŞ  
Ağrı Maternity Hospital,  
Clinic of Gynecology and Obstetrics,  
Ağrı,  
TÜRKİYE/TURKEY  
drmuratakbas@yahoo.com.tr

**ABSTRACT** Uterine rupture is one of the life-threatening obstetric complication affecting the pregnant woman and fetus. Most of the cases occur during the second or third trimester. Uterine rupture in the first trimester of pregnancy occurs extremely rarely. Emergency surgical intervention is needed for accurate diagnosis and immediate management. We present a case of spontaneous uterine rupture which occurred at twelve weeks of gestation from left uterine vessels side with massive retroperitoneal hematoma. In the literature, this is the first spontaneous uterine rupture case with vessel injury and retroperitoneal hematoma in first trimester. The case was misdiagnosed as ruptured ectopic pregnancy by both radiologist and gynecologist because of uncertain ultrasound findings. Emergency laparotomy confirmed a spontaneous uterine rupture. Clinical signs of uterine rupture are nonspecific at first trimester. Uterine rupture must take a place in differential diagnosis of acute abdominal emergencies of pregnant woman.

**Key Words:** Uterine rupture; hematoma; pregnancy trimester, first

**ÖZET** Uterus rüptürü gebenin ve fetüsün hayatını tehdit eden obstetrik komplikasyonlardan biridir. Vakaların çoğunluğu ikinci veya üçüncü trimesterde gelişmektedir. İlk trimesterde gerçekleşen uterus rüptürü oldukça nadirdir. Kesin tanı ve hızlı tedavi için acil cerrahi müdahale gerekmektedir. Sunduğumuz olguda; onikinci gebelik haftasında gelişen ve sol uterin damarları da içeren spontan rüptüre masif retroperitoneal hematoma eşlik etmektedir. Literatürde, ilk trimesterde damar yaralanması ve retroperitoneal hematomun eşlik ettiği ilk spontan uterus rüptürü vakasıdır. Bu olgu net olmayan ultrason bulguları nedeniyle hem radyolog hem de jinekolog tarafından ektopik gebelik ön tanısını almıştır. Acil laparotomi ile spontan uterus rüptürü tanısı konmuştur. İlk trimesterde gelişen uterus rüptürünün bulguları net olmayabilir. Uterus rüptürü akut batın gelişen gebelerin ayırıcı tanısında dikkate alınmalıdır.

**Anahtar Kelimeler:** Uterus rüptürü; hematoma; gebelik trimesteri, birinci

**Türkiye Klinikleri J Gynecol Obst 2015;25(3):205-8**

Uterine rupture is one of the most dangerous obstetric situations, carrying an increased risk of maternal and perinatal morbidity and mortality.<sup>1,2</sup> There are several risk factors associated with uterine rupture but the most common one is previous cesarean section. Unscarred uterine rupture is a rare event that usually occurs in late pregnancy or during labour. It is reported that spontaneous rupture of unscarred uterus occurs in 1 in 15,000.<sup>3</sup> Usually the patient is presented with acute abdominal pain and intraperitoneal hemorrhage. In the literature there is no case describing first trimester spontaneous uterine rupture with retroperitoneal hematoma.

doi: 10.5336/gynobstet.2014-39032

Copyright © 2015 by Türkiye Klinikleri

We here report a case of a spontaneous uterine rupture with uterine vessels injury at first trimester of pregnancy with retroperitoneal hematoma.

## CASE REPORT

A 36 years old gravida 8 para 7 woman was admitted to our emergency clinic, complaining of diffuse abdominal pain for two days with 12 weeks of amenorrhea. Patient had not any antenatal visit and pregnancy had not been confirmed before. Her past obstetric history consisted of seven spontaneous vaginal deliveries at term.

On physical examination, vital signs was stable, abdomen was distended with diffuse abdominal pain and rebound tenderness was evident. Vaginal examination revealed spotting type of bleeding. Cervical motion tenderness was positive and uterine size could not assessed but fullness felt in pouch of douglas. Ultrasound scan of abdomen and pelvis revealed the 12 weeks sized ectopic pregnancy with 10x5 cm fluid collection in the right adnexal side and heterogenous uterus with increased in size (Figure 1). Routine blood tests (full blood count, electrolytes, renal and liver function tests and coagulation parameters) showed no abnormalities at the time of admittance. But during follow up, her hemoglobin was decreased from 12,3 g/dl to 9,8 g/dl in two hours.

In this context, emergency operation was determined with the diagnosis of ectopic pregnancy. Before the operation informed consent was ob-

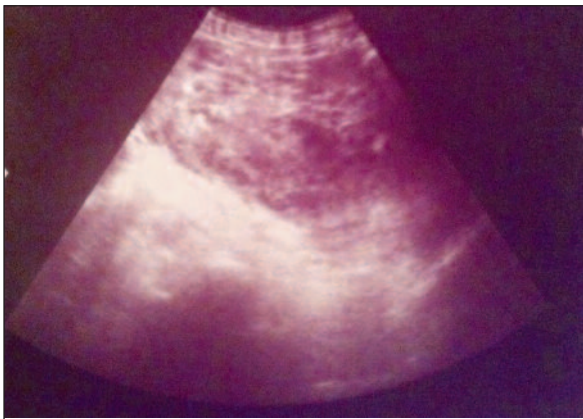


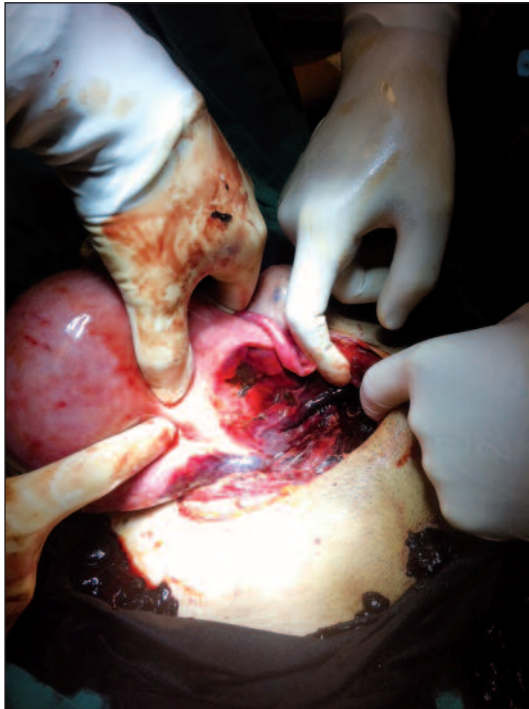FIGURE 1: Pelvic hematoma.

tained from patient. The patient wanted no more pregnancy and approved hysterectomy if needed. Laparotomy was performed and revealed a large amount of blood clots in the pelvic and abdominal cavity. After removing the blood clots we understood that organised blood cloth in the pelvis was misdiagnosed as heterogenous uterus and 12 weeks of intrauterine pregnancy with uterine rupture was misdiagnosed as ruptured right adnexal ectopic pregnancy. Uterus was ruptured at the side of left uterine vessels. Rupture was extended to cervix. Large retroperitoneal hematoma was observed (Figure 2, 3). 3 cm incision was made at fundus of uterus to perform suction of gestational material. After consulting the patient we decided to perform hysterectomy because of vessel injury, uterine hematoma and large retroperitoneal hematoma. After hysterectomy was performed peritoneum was opened and hematoma was removed, one drainage tube was placed in the abdominal cavity and another one was placed in the retroperitoneum and then the abdominal cavity was closed. The patient's postoperative recovery was uneventful and she was discharged on her third postoperative day. Pathology report showed no finding which could be a risk factor for uterine rupture.

Written informed consent was obtained from the patient for publication of this case report and accompanying images.

## DISCUSSION

Most of the uterine rupture cases had various risk factors.<sup>4</sup> Uterine scar is the most important risk factor for rupture.<sup>1</sup> It is reported that spontaneous rupture of unscarred uterus occurs in 1 in 15,000.<sup>3</sup> It may occur in cases of placenta increta or percreta, adenomyosis, manipulation during delivery, induced delivery by misoprostol.<sup>5</sup> It may also occur in patients with high parity at higher rates.<sup>6</sup> In most cases, uterine rupture occurs just before or during labor. First trimester unscarred uterine ruptures are very rare, and there are only a few cases in literature. Young-Joon et al. presented a case of spontaneous uterine rupture with hemoperitoneum at 6<sup>th</sup> gestational weeks. Small uterine rupture (3 mm) was observed on the upper portion of the left fun-



**FIGURE 2:** Uterine rupture from left uterine wall including vessels.

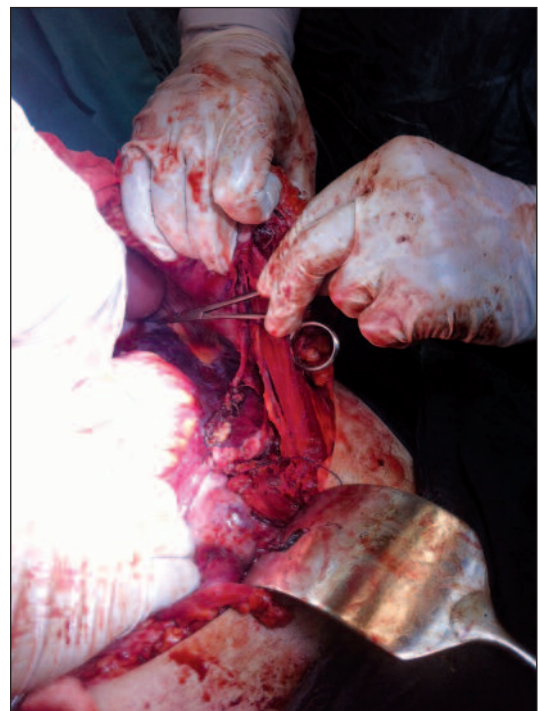
dus and repaired with one layer of suture after suction of gestational material.<sup>7</sup> Singh et al. and Kahyaoglu et al. previously reported uterine rupture cases with uterine anomaly in the first trimester.<sup>8,9</sup> Tola presented a case at 12 weeks of gestation with bicornuate uterus. In this case 2 cm fundal uterine rupture in the left part of the uterus was repaired.<sup>10</sup> In our case, there were no any obvious risk factor.

Uterine rupture is a serious condition because of massive bleeding. Bleeding may not be intraabdominal only, it can be retroperitoneal like in our case. Retroperitoneal hematoma may not be easily diagnosed with ultrasound. Immediate management can be delayed because of misdiagnoses. Uterine rupture can be misdiagnosed as ectopic pregnancy in the first trimester. Uterine rupture should be kept in mind in the differential diagnosis of acute abdominal pain in the first trimester of pregnancy. The case we presented was misdiagnosed as fetal heart beat positive ectopic pregnancy due to uncertain ultrasound scan findings. Hematoma in the pelvic cavity resembled het-

erogenous uterus. Uterus was shifted to right side of pelvis and this condition led to misdiagnosis.

Unscarred uterine rupture usually occurs in the lower segment (the weakest part) of uterus.<sup>11</sup> If the ruptured part is the fundus, the diagnosis is often delayed because the hemorrhage is not revealed immediately, as blood collects in the intraperitoneal space.<sup>11</sup> In our case, hemorrhage was predominantly retroperitoneal and there was no free fluid in the intraabdominal space.

Early surgical intervention is the key to successful treatment of uterine rupture. Treatment will primarily depend on the extent of the lesion, the parity, age and condition of the patient, and expertise of the surgeon. The suture can be performed in women who wish to preserve fertility with a recurrence risk of uterine rupture assessed to be between 4 and 19% at a subsequent pregnancy.<sup>12</sup> In our case, rupture extended to cervix, left uterine vessels were injured and there was large retroperitoneal hematoma. Hemodynamic condition was not stable and patient did not wish to preserve fertility. In this context, we decided to perform hysterectomy.



**FIGURE 3:** Retroperitoneal hematoma.

## CONCLUSION

Close follow up and intensive surgical method would be needed for accurate diagnosis and immediate treatment in the cases of uterine rupture in the

first trimester. Treatment will primarily depend on the extent of the lesion, the parity, age and condition of the patient. In our case, we performed total hysterectomy because left uterine vessels were injured and led to massive retroperitoneal hematoma.

## REFERENCES

1. Turner MJ. Uterine rupture. *Best Pract Res Clin Obstet Gynaecol* 2002;16(1):69-79.
2. Kieser KE, Baskett TF. A 10-year population-based study of uterine rupture. *Obstet Gynecol* 2002;100(4):749-53.
3. Sallam AH, Preston J. Idiopathic uterine perforation in late pregnancy. *J Obstet Gynaecol* 2002;22(3):317.
4. Suner S, Jagminas L, Peipert JF, Linakis J. Fatal spontaneous rupture of a gravid uterus: case report and literature review of uterine rupture. *J Emerg Med* 1996;14(2):181-5.
5. Berghahn L, Christensen D, Droste S. Uterine rupture during second-trimester abortion associated with misoprostol. *Obstet Gynecol* 2001;98(5 Pt 2):976-7.
6. Miller DA, Goodwin TM, Gherman RB, Paul RH. Intrapartum rupture of the unscarred uterus. *Obstet Gynecol* 1997;89(5 Pt 1):671-3.
7. Park YJ, Ryu KY, Lee JI, Park MI. Spontaneous uterine rupture in the first trimester: a case report. *J Korean Med Sci* 2005;20(6):1079-81.
8. Singh A, Jain S. Spontaneous rupture of unscarred uterus in early pregnancy--a rare entity. *Acta Obstet Gynecol Scand* 2000;79(5):431-2.
9. Kahyaoglu S, Turgay İ, Kaymak O, Kalyoncu Ş, Mollamahmutoğlu L. [Pregnancy and uterine rupture during seventeen weeks of gestation: case report]. *J Perinatol* 2005;13(3):179-82.
10. Tola EN. First trimester spontaneous uterine rupture in a young woman with uterine anomaly. *Case Rep Obstet Gynecol* 2014;2014:967386. doi: 10.1155/2014/967386.
11. Misra M, Roychowdhury R, Sarkar NC, Koley MM. The spontaneous prelabour rupture of an unscarred uterus at 34 weeks of pregnancy. *J Clin Diagn Res* 2013;7(3):548-9.
12. Ahmadi S, Nouira M, Bibi M, Boughuizane S, Saidi H, Chaib A, et al. [Uterine rupture of the unscarred uterus. About 28 cases]. *Gynecol Obstet Fertil* 2003;31(9):713-7.