

CASE REPORT

DOI: 10.5336/jcog.2022-94581

Uterine Rupture as a Rare Complication in Pregnancies After Laparoscopic Myomectomy

¹ Canan SATIR ÖZEL^a, ² Ömer İlker GÖÇMEN^a, ³ Oğuz Devrim YARDIMCI^a, ⁴ Mehmet KÜÇÜKBAŞ^a,
⁵ Ateş KARATEKE^b

^aClinic of Obstetrics and Gynecology, Göztepe Prof. Dr. Süleyman Yalçın City Hospital, İstanbul, Türkiye

^bDepartment of Obstetrics and Gynecology, İstanbul Medeniyet University Faculty of Medicine, İstanbul, Türkiye

ABSTRACT Uterine leiomyomas can be treated with myomectomy. But there is a concern of uterine rupture in patients treated with myomectomy. The risk of rupture is higher in laparoscopic myomectomy than in laparotomic myomectomy. It may be related to the difference in surgical methods. Uterine rupture can be caused by previous surgical scars during labour or uterine enlargement with the progression of pregnancy. Here, we present two cases of uterine rupture occurred in laparoscopic myomectomy scar in the second trimester. It should be kept in mind that rupture may develop after myomectomy and be considered in patients with abdominal pain and bleeding during pregnancy. Maternal and fetal morbidity and mortality may increase with delayed diagnosis and treatment.

Keywords: Case report; laparoscopic myomectomy; pregnancy; uterine rupture

Uterine leiomyomas are the most common tumors of the reproductive system. Myomectomy is the preferred one to preserve fertility. However, there are concerns about the risk of uterine rupture in pregnancies after myomectomy. Partial rupture is defined as subperitoneal myometrium dehiscence, although, complete rupture involves the whole layers of uterus.¹ Uterine rupture is an emergency that threatens the life of mother and fetus.² Rupture presents with an abnormal fetal heartbeat, abdominal pain, vaginal bleeding, and loss of fetal presentation.¹ Uterine rupture can occur in labour or during pregnancy before labour. It may also develop in an unscarred uterus.

In this paper, we present 2 cases of uterine rupture in *in vitro* fertilization (IVF) pregnancies after laparoscopic (L/S) myomectomy before labour.

CASE REPORTS

CASE 1

A 33 years old, gravida one, 27+3 weeks pregnant was accepted to our emergency service with the complaint of abdominal pain and vaginal spotting for days. She had a history of L/S myomectomy for a 3×2 cm subserous leiomyoma in posterior uterine corpus. Her pregnancy was an IVF pregnancy achieved in 18th month after myomectomy. On examination, we detected tenderness, defense, and rebound in her abdomen and vaginal spotting. Transvaginal ultrasound revealed an intact amniotic sac prolonged from the posterior corpus to abdominal cavity containing fetal leg (Video 1). An emergency laparotomy (L/T) was planned because of uterine

Makalenin videosu için:



Video 1: The area of complete rupture from the posterior aspect of the uterus, the bulging amniotic sac, and the fetal limb in the sac.

Correspondence: Canan SATIR ÖZEL

Clinic of Obstetrics and Gynecology, Göztepe Prof. Dr. Süleyman Yalçın City Hospital, İstanbul, Türkiye

E-mail: drcanansatirozel@gmail.com

Peer review under responsibility of Journal of Clinical Obstetrics & Gynecology.

Received: 29 Nov 2022

Accepted: 09 Feb 2023

Available online: 13 Feb 2023

2619-9467 / Copyright © 2023 by Türkiye Klinikleri. This is an open access article under the CC BY-NC-ND license (<http://creativecommons.org/licenses/by-nc-nd/4.0/>).



rupture diagnosis. Upon abdominal entry, we detected 100 mL of blood. We opened the uterus with transverse Kerr incision and delivered a live female fetus. In exploration, we detected a 5-6 cm complete rupture in the posterior corpus (Figure 1). Upon closure of the Kerr incision continually, the first layer of the rupture was repaired with separate figure of eight sutures and the second layer with separate horizontal matrix sutures (Figure 2). Polyglactin 1 suture was used in the whole uterine repair. The patient was uneventfully discharged on the 4th postoperative day. Umbilical cord blood gas pH was 7.45. First and fifth minute Apgar scores was 4. The baby was hospitalized in neonatal intensive care unit for 39 days and developed respiratory distress, sepsis, and retinopathy. Following recovery, the baby was transferred into regular hospital room and discharged on the 49th day of hospitalization.

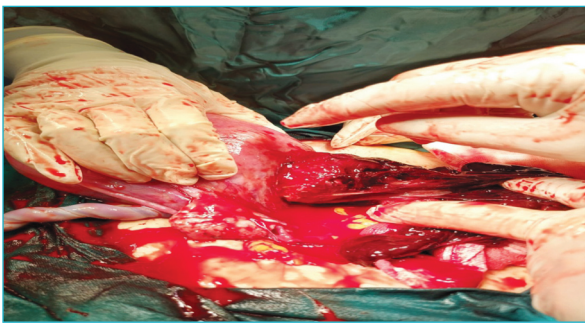


FIGURE 1: The protrusion of the amniotic sac and its appendages from the rupture area from the posterior uterus after delivery of the fetus.

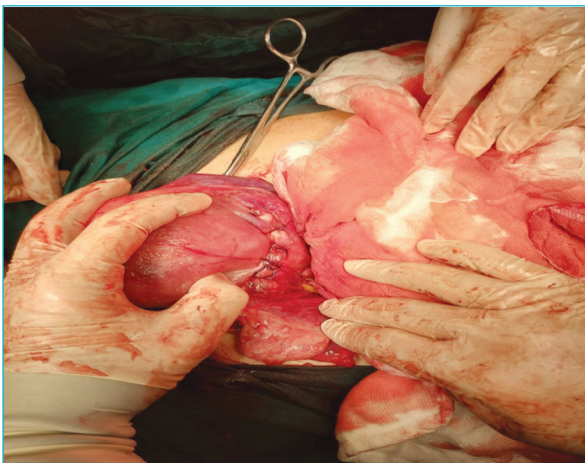

FIGURE 2: Rupture area after the repair.

CASE 2

A 41-year-old, gravida one, 26+2 weeks pregnant was accepted to emergency service with the complaint of abdominal pain. On general surgeon's consultation, an emergency L/T was decided due to abdominal defense on her physical examination and vast amount of abdominal free fluid in ultrasonographic examination. There was 1,500 mL blood and a 8 cm complete rupture in uterine fundus. As an obstetrician team, we attended the operation for intraoperative consultation. We detected an intact amniotic sac bulging through the abdominal cavity from uterine fundus. The fetus was delivered by amniotomy. The first layer of the ruptured part was closed with continuous locked sutures, and the second layer with separated horizontal sutures. We used polyglactin 1 in closure. In postoperative period, 2 units of fresh frozen plasma and 1 unit of erythrocyte suspension were replaced. She underwent L/S myomectomy one year ago. She conceived with IVF 6 months after myomectomy. After newborn resuscitation, the baby was intubated in the operating room. Umbilical cord blood gas pH was 6.8. First minute Apgar score was 2 and fifth minute Apgar score was 7. Upon development of respiratory distress, pulmonary hypertension, sepsis, hypoxic-ischemic encephalopathy, pulmonary hemorrhage, Grade 4 intravascular hemorrhage in neonatal intensive care unit, the baby died on the postpartum 12th day.

Written informed consent was obtained from both patients for publication of these case reports and accompanying images. Ethics committee approval was not required as they were a case reports.

DISCUSSION

Myomectomy, which can be performed via L/S and L/T, is the primary surgical method in women who want to preserve their fertility. However, there is a concern about uterine rupture that may occur in subsequent pregnancies. The risk of uterine rupture was reported as 4.23/1,000 operations and 10.53/1,000 operations in L/T and L/S myomectomy, respectively.³

Uterine rupture risk factors are obstructed labour, multiparity, use of uterotonics, intrauterine

manipulations such as internal podalic version, placenta percreta, previous cesarean, malpresentation, use of vacuum and forceps, myomectomy history, and accidents.⁴⁻⁸ In both patients, the rupture was occurred in the L/S myomectomy scar in the second trimester. Maternal consequences of uterine rupture may be profuse bleeding, emergency hysterectomy, bladder injury, major puerperal infection, longer hospital stay, and fetal death.^{1,2,9}

Classical surgical recommendations for myomectomy are to enucleate as many leiomyomas from as few incisions as possible, to avoid incisions from the posterior uterus, to prefer a vertical incision in fundus, to ensure careful hemostasis, adequate approximation of the myometrium and serosa, while layering with polyglactin 0 sutures without leaving any dead space in myometrium to prevent hematoma, to close serosal margins with 3-0 or 4-0 delayed-absorbable “base-ball” sutures.¹⁰ In L/S myomectomy, it is thought that tissue healing is weaker compared to L/T myomectomy due to factors such as the use of excessive electrosurgery and consequential tissue necrosis, insufficient multilayer suturing, and the effect of carbon dioxide on healing.⁹

Uterine rupture should be kept in mind in pregnancies of the patients with a history of myomectomy. Rate of uterine rupture in L/S myomectomy

may be higher from L/T myomectomy. When these patients present with abdominal pain and bleeding, uterine rupture should be in differential diagnosis. A quick intervention may be life-saving for both mother and fetus.

Source of Finance

During this study, no financial or spiritual support was received neither from any pharmaceutical company that has a direct connection with the research subject, nor from a company that provides or produces medical instruments and materials which may negatively affect the evaluation process of this study.

Conflict of Interest

No conflicts of interest between the authors and / or family members of the scientific and medical committee members or members of the potential conflicts of interest, counseling, expertise, working conditions, share holding and similar situations in any firm.

Authorship Contributions

Idea/Concept: Canan Satır Özel; **Design:** Canan Satır Özel; **Control/Supervision:** Mehmet Küçükbaş, Oğuz Devrim Yardımcı; **Data Collection and/or Processing:** Canan Satır Özel, Ömer İlker Göçmen; **Analysis and/or Interpretation:** Canan Satır Özel; **Literature Review:** Oğuz Devrim Yardımcı; **Writing the Article:** Canan Satır Özel; **Critical Review:** Mehmet Küçükbaş, Ateş Karateke; **References and Fundings:** Ömer İlker Göçmen; **Materials:** Ömer İlker Göçmen.

REFERENCES

- Guiliano M, Closset E, Therby D, LeGoueff F, Deruelle P, Subtil D. Signs, symptoms and complications of complete and partial uterine ruptures during pregnancy and delivery. *Eur J Obstet Gynecol Reprod Biol.* 2014;179:130-4. [[Crossref](#)] [[PubMed](#)]
- Lydon-Rochelle M, Holt VL, Easterling TR, Martin DP. Risk of uterine rupture during labor among women with a prior cesarean delivery. *N Engl J Med.* 2001;345(1):3-8. [[Crossref](#)] [[PubMed](#)]
- Gil Y, Badeghiesh A, Suarhana E, Mansour F, Capmas P, Volodarsky-Perel A, et al. Risk of uterine rupture after myomectomy by laparoscopy or laparotomy. *J Gynecol Obstet Hum Reprod.* 2020;49(8):101843. [[Crossref](#)] [[PubMed](#)]
- Neilson JP, Lavender T, Quenby S, Wray S. Obstructed labour. *Br Med Bull.* 2003;67:191-204. [[Crossref](#)] [[PubMed](#)]
- Topuz S. Spontaneous uterine rupture at an unusual site due to placenta percreta in a 21-week twin pregnancy with previous cesarean section. *Clin Exp Obstet Gynecol.* 2004;31(3):239-41. [[PubMed](#)]
- Ofir K, Sheiner E, Levy A, Katz M, Mazor M. Uterine rupture: risk factors and pregnancy outcome. *Am J Obstet Gynecol.* 2003;189(4):1042-6. [[Crossref](#)] [[PubMed](#)]
- Chao AS, Chang YL, Yang LY, Chao A, Chang WY, Su SY, et al. Laparoscopic uterine surgery as a risk factor for uterine rupture during pregnancy. *PLoS One.* 2018;13(5):e0197307. [[Crossref](#)] [[PubMed](#)] [[PMC](#)]
- van Enk A, van Zwam W. Uterine rupture. A seat belt hazard. *Acta Obstet Gynecol Scand.* 1994;73(5):432-3. [[Crossref](#)] [[PubMed](#)]
- Parker WH, Einarsson J, Istre O, Dubuisson JB. Risk factors for uterine rupture after laparoscopic myomectomy. *J Minim Invasive Gynecol.* 2010;17(5):551-4. Erratum in: *J Minim Invasive Gynecol.* 2010;17(6):809. [[Crossref](#)] [[PubMed](#)]
- Guarnaccia MM, Rein MS. Traditional surgical approaches to uterine fibroids: abdominal myomectomy and hysterectomy. *Clin Obstet Gynecol.* 2001;44(2):385-400. [[Crossref](#)] [[PubMed](#)]