

Hyperreactio Luteinalis in Twin Pregnancy Mimicking Malignancy: Case Report

İkiz Gebelikte Malign Gibi Davranan Benign Kitle

Gamze UYANIK,^a
Emre Erdem TAŞ,^a
Hüseyin Levent KESKİN,^a
Ayşe Filiz AVŞAR^a

^aClinic of Gynecology and Obstetrics,
Ankara Atatürk Training and
Research Hospital, Ankara

Geliş Tarihi/Received: 11.06.2013
Kabul Tarihi/Accepted: 15.04.2014

Yazışma Adresi/Correspondence:
Gamze UYANIK
Ankara Atatürk Training and
Research Hospital,
Clinic of Gynecology and Obstetrics,
Ankara,
TÜRKİYE/TURKEY
gamze_u@hotmail.com

ABSTRACT Most adnexal masses in pregnancy are diagnosed incidentally in the first trimester. Most of these are benign, asymptomatic and spontaneously disappear by 16 weeks of gestation. But some of the masses may persist and may cause serious problems, such as torsion, rupture, obstruction to vaginal delivery and delay of malignancy diagnosis. Ultrasonography is the first-line imaging modality used for evaluating adnexal masses. Ultrasound characterization of the complexity and size of the adnexal mass can assist with the prediction of malignancy. Making the decision to operate an adnexal mass diagnosed in pregnancy is often difficult. Some investigators recommend expectant management and others recommend surgical management. The obstetrician must balance the risks and benefits of surgery or observation by taking both mother and fetus into account. In this report, we present a case of huge, multiloculated ovarian benign cyst in twin pregnancy which grew rapidly during the second trimester, like a malignant mass and managed surgically.

Key Words: Pregnancy, twin; laparotomy; cystectomy

ÖZET Gebelikteki çoğu adneksiyal kitleler ilk trimesterde tesadüfen teşhis edilirler. Bunların pek çoğu benign ve asemptomatiktir ve 16. gebelik haftasında spontan olarak yok olur. Fakat bazıları sebat edebilir ve torsiyon, rüptür, doğumu zorlaştırma ve malignitenin tanınmasını geciktirme gibi ciddi problemlerle sonuçlanabilir. Adneksiyal kitleleri görüntülemek için öncelikli araç ultrasonografidir. Bir adneksiyal kitlenin sonografik görüntüleme özellikleri, büyüklüğü ve anatomik kompleks yapısı, malignite tahmininde yardımcı olabilir. Gebelikte teşhis edilen bir adneksiyal kitle için operasyon kararı vermek genellikle zordur. Bazı araştırmacılar gözlemsel yaklaşımdan yana iken diğerleri cerrahi tedaviden yanadırlar. Bir kadın doğum uzmanı hem anne hem de fetusu göz önüne alarak gözlem ya da cerrahi tedavinin risk ve faydalarını iyi dengelemek zorundadır. Bu olgu raporunda; ikiz bir gebelikte özellikle ikinci trimesterde süratle büyüyen, septasyon gösteren, malign bir kitleyi taklit eden ve cerrahi olarak tedavi edilen benign bir kitle sunulmuştur.

Anahtar Kelimeler: İkiz gebeliği; laparotomi; sistektomi

Türkiye Klinikleri J Gynecol Obst 2014;24(2):126-9

The incidence of adnexal masses during pregnancy is 1-8%. Most of them are small (≤ 5 cm) and disappear spontaneously in early weeks of gestation.¹⁻⁴ But sometimes these may persist throughout pregnancy or have complex features. In management; it's important to identify that the mass have benign or malign characteristics. There are two options for management of ovarian masses in pregnancy; expectant management or surgery. Surgical management is indicated in symptomatic patients and in suspicion of malignant.

CASE REPORT

A 24 year old, primigravida was referred to our clinic at 17 weeks' spontaneous twin pregnancy following ultrasound scan that revealed unilateral large ovary with multiple anechoic cysts. Her complaints were abdominal pain and tightness; started at 12 weeks of gestation and increased progressively during 5 weeks. Early in her pregnancy; transvaginal ultrasonography disclosed two intrauterin gestational sacs containing two embryos; crown rump lengths of 24 and 27 mm; corresponding to 9⁺4 and 10⁰ weeks gestation. Enlarged ovary was not detected at that scan. The patient had never taken drugs to induce ovulation. Her medical gynecological and surgical history were unremarkable. On physical examination the patient had an asymmetrical distention of the abdomen and adnexal mass about 20 cm on the left side of the gravid uterus was palpated. Uterus whose size was consistent with 20 weeks' gestation and depressed to the right side of abdomen. Vaginal examination revealed large mobile unilateral mass that filled the pouch of Douglas. There were no signs of peritoneal irritation. No evidence of thyroid disease or hyperandrogenism was noted. An ultrasound scan was showed an intrauterin dicorionic diamniotic twin pregnancy consistent with gestational age. On the left adnexal region there was voluminous multilocular cyst with septa and echogenic foci reached the level of splenic area. Magnetic resonance of the abdomen showing a 20 cm diameter huge multiloculated cystic mass, neighboring the left uterine wall and spleen, displaced uterus to right side

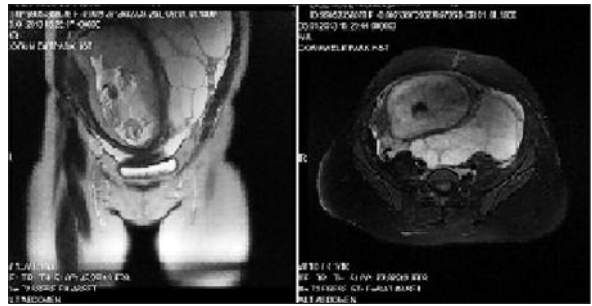


FIGURE 1, 2: Coronal T2(1) and fat-suppressed T2(2) images demonstrating huge multiloculed cystic mass, neighbouring the left uterine wall and spleen, displaced uterus to right side.

(Figure 1, 2). Blood analysis of tumor markers was CA125: 137 IU/mL, CA19-9: 11 kU/L, CA15-3: 26 kU/L, AFP: 28 ng/mL. Owing to the progressive growth of the mass, reaching the level of the umbilicus, the mass was suspected to be malign tumor of the ovary and the patient was referred for surgery. Surgery was performed at 18 weeks of gestation using a midline incision. Laparotomic exploration revealed a voluminous multiloculated cyst about 19*17*5 cm. The cyst had reached the level of the umbilicus and filled the entire paracolic area. There was some solid areas with necrosis (Figure 3). No ovarian tissue was left and left salpingo-oophorectomy was performed. Another cyst which reached the level of the spleen was seen after left adnexectomy. The cyst was originated from the right ovary and shifted to left behind uterus. The cyst had same characteristics with the first one and measured 18*14*5 cm. there was a little normal ovarian tissue. A right partial oophorectomy was performed. The patient's post-operative course was

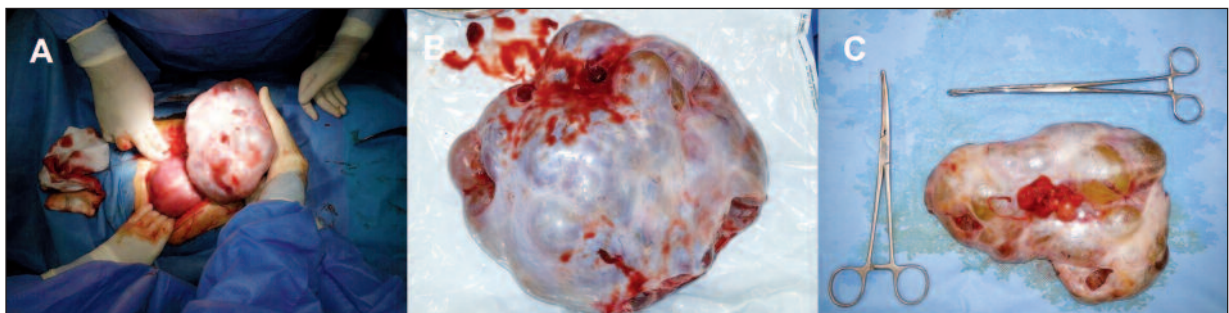


FIGURE 3: A. Intraoperative appearance of the cysts. B. Left salpingo-oophorectomy with no ovarian tissue. C. Right partial oophorectomy.

(See color figure at <http://www.turkiyeklinikleri.com/journal/jinekoloji-obstetrik-dergisi/1300-0306/>)

uncomplicated with no bleeding and contractions. She was discharged from hospital 7 days after the surgery. The pathologic result was hyperreactio luteinalis (HL). Patient was controlled after 4 weeks from the surgery in 21 weeks' of gestation. There were no complications. Pregnancy was terminated by elective caesarean section in 37th gestation weeks because of breech/breech indication. Both newborn and patient examination was normal.

DISCUSSION

Most adnexal masses in pregnancy are diagnosed incidentally in the first trimester with widespread use of antenatal ultrasound.¹⁻³ Most of them are asymptomatic. A functional cyst is the most common adnexal mass in pregnancy and usually resolves spontaneously by 16 weeks of gestation.⁴ Ovarian malignancy accounts for approximately 1-8% of adnexal masses in pregnancy.^{1,5-7}

Ultrasonography is the first-line imaging modality used for evaluating adnexal masses during pregnancy. Ultrasound characterization of the mass, like complexity and size may assist with the prediction of malignancy. Characteristics suggestive of malignancy are masses with septations, solid components, nodules, papillary components or an average size of greater than 5 cm in diameter. But there is still not a deal about the size of masses. For the up to 20% of sonographically indeterminate adnexal lesions, magnetic resonance imaging (MRI) is used as a second-line imaging modality.⁸ MRI is useful in evaluating adnexal masses that are too large to be accurately evaluated by ultrasonography (USG) and preferred to computed tomography based on its better soft tissue resolution and ability to avoid fetal exposure to ionizing radiation. MRI interpretations correlated with pathologic examination in the vast majority of cases.⁹

Making the decision to operate an adnexal mass diagnosed in pregnancy is often difficult. Some investigators recommends observation and others surgical management.^{1,3,5,7} Most of ovarian masses identified in pregnancy often spontaneously resolve and aggressive surgical manage-

ment is not required. Adnexal masses, that are simple in nature by USG examination less than 5-6 cm in diameter and diagnosed before 16 weeks of gestation are the predictive factors for spontaneous resolution.¹⁰ Larger masses or those with more complex morphology are less likely to spontaneously disappear and may represent a neoplastic process.⁵⁻⁷ Persistent adnexal masses can also be complicated with torsion (1-22%), rupture (0-9%) or obstruction of labor (2-17%).^{1,2,5,6} Observation is viable for patients who are clinically asymptomatic and whose mass appears benign with no evidence of malignancy noted on imaging. Surgical management should be preferred for masses which are symptomatic (pain, torsion, rupture, hemorrhage), persist into the second trimester, >10 cm diameter in size, solid or have mixed solid and cystic ultrasound features or have suspicion for malignancy. There are some risks of surgery like miscarriage, premature rupture of membranes, preterm delivery and increased rate of thrombotic events. Surgery should be performed ideally in the second trimester (12-27 weeks).¹¹

In this case; the mass's size was greater than 20 cm and had increased progressively during last 5 weeks. The patient became symptomatic; had abdominal pain and tightness. Unilateral, multiloculated and huge cystic lesion was demonstrated both USG and MRI. We could not rule out an ovarian malignancy. Therefore, surgical management was performed in 17 weeks of gestation. There were no intra and postoperative complications. The pathologic result was HL. It is a rare and benign condition which occurs when patients have increased sensitivity to circulating hCG and is characterized by multiple cysts and bilateral ovarian enlargement. Typically manifests in the third trimester of pregnancy. And spontaneous regression of cysts is seen after delivery. It is important to differentiate HL from malignant ovarian tumors to avoid unnecessary surgery. Although it is not always possible; the laboratory findings of high levels of hCG and normal levels of ovarian tumor markers, in combination with such imaging methods as USG and MRI, can help differentiate HL from malignant ovarian masses.

The decision of expectant or surgical management of an adnexal mass should be based on primarily the patient's symptoms, imaging features and the suspicion of malignancy. The obstetrician must balance the risks and benefits of surgery or expectation for both mother and fetus. Observation is a viable option for those who are asymptomatic and whose mass appears benign with no evidence of malignancy noted on imaging. For patients with a complex mass, possibly suspicion of a malig-

nancy, expectant management can also be offered until delivery or postpartum as an acceptable option. The decision whether to postpone surgical management of a complex mass until the time of delivery or postpartum must balance the risks and benefits, weighing the risks of malignancy vs the potential for unnecessary surgical risks for mother and fetus.¹² Therefore; the obstetrician must be skilled in the diagnosis and management of adnexal masses in pregnancy.

REFERENCES

1. Leiserowitz GS. Managing ovarian masses during pregnancy. *Obstet Gynecol Surv* 2006;61(7):463-70.
2. Glanc P, Salem S, Farine D. Adnexal masses in the pregnant patient: a diagnostic and management challenge. *Ultrasound Q* 2008;24(4):225-40.
3. Giuntoli RL 2nd, Vang RS, Bristow RE. Evaluation and management of adnexal masses during pregnancy. *Clin Obstet Gynecol* 2006; 49(3):492-505.
4. Türkçüoğlu I, Meydanlı MM, Engin-Ustün Y, Ustün Y, Kafkaslı A. Evaluation of histopathological features and pregnancy outcomes of pregnancy associated adnexal masses. *J Obstet Gynaecol* 2009;29(2):107-9.
5. Schmeler KM, Mayo-Smith WW, Peipert JF, Weitzen S, Manuel MD, Gordinier ME. Adnexal masses in pregnancy: surgery compared with observation. *Obstet Gynecol* 2005;105(5 Pt 1):1098-103.
6. Whitecar MP, Turner S, Higby MK. Adnexal masses in pregnancy: a review of 130 cases undergoing surgical management. *Am J Obstet Gynecol* 1999;181(1):19-24.
7. Bromley B, Benacerraf B. Adnexal masses during pregnancy: accuracy of sonographic diagnosis and outcome. *J Ultrasound Med* 1997;16(7):447-52;quiz 453-4.
8. Adusumilli S, Hussain HK, Caoili EM, Weadock WJ, Murray JP, Johnson TD, et al. MRI of sonographically indeterminate adnexal masses. *AJR Am J Roentgenol* 2006;187(3): 732-40.
9. Birchard KR, Brown MA, Hyslop WB, Firat Z, Semelka RC. MRI of acute abdominal and pelvic pain in pregnant patients. *AJR Am J Roentgenol* 2005;184(2):452-8.
10. Levine D, Brown DL, Andreotti RF, Benacerraf B, Benson CB, Brewster WR, et al.; Society of Radiologists in Ultrasound. Management of asymptomatic ovarian and other adnexal cysts imaged at US Society of Radiologists in Ultrasound consensus conference statement. *Ultrasound Q* 2010;26(3): 121-31.
11. Ko ML, Lai TH, Chen SC. Laparoscopic management of complicated adnexal masses in the first trimester of pregnancy. *Fertil Steril* 2009;92(1):283-7.
12. Hoover K, Jenkins TR. Evaluation and management of adnexal mass in pregnancy. *Am J Obstet Gynecol* 2011;205(2): 97-102.